Canon

Ultrasound / White paper

Role of ultrasound examination in gynecology oncology: Standard applications and innovative techniques

Giuliana Beneduce, Floriana Mascilini, Antonia Carla Testa (photo), Francesca Moro
Department of Women, children and public health sciences,
Fondazione Policlinico Universitario Agostino Gemelli IRCCS
Rome, Italy

Introduction

Ultrasound plays a fundamental role in gynecologic oncology in the preoperative assessment of gynecologic tumors and during follow-up. For the assessment of adnexal masses, transvaginal ultrasound examination is an excellent tool able: 1) to identify pelvic lesions; 2) to discriminate between benign and malignant ovarian masses; 3) to assess the disease extension in the pelvic/abdominal cavity.

Calculating a risk of ovarian malignancy

There are more than 20 years of literature about the discrimination between benign and malignant masses that teach us how to correctly define and collate ovarian lesions, not only using subjective assessment, but recently also using prediction models developed by the International Ovarian Tumor Analysis (IOTA) group[1]. The most used IOTA models are Simple Rules (SRs)[2], Simple Rules risk (SRrisk) model[3], and Assessment of Different NEoplasias in the adneXa (ADNEX)[4]. The SRs are based on five ultrasound features suggestive of a benign lesion (B-features) and five ultrasound features suggestive of a malignant lesion (M-features). In cases where neither M- nor B-rules apply, or where both are present, the mass is classified as "inconclusive" and further investigations are required. Therefore, the SRrisk model was developed. It uses the number of benign or malignant ultrasound features present in a mass to calculate a risk of malignancy. The IOTA ADNEX model calculates not only the percentage risk of an adnexal mass being benign or malignant but the likelihood that the mass is benign, borderline, stage I primary invasive malignancy, stage II-IV primary invasive malignancy or a metastasis in the ovary from another primary tumor (Figs. 1-4).

In addition, European and North American gynecologists and radiologists have developed a management system for adnexal masses based on either specific ultrasound features or on the risk of malignancy calculated by ADNEX. This system classifies masses into different risk groups of malignancy and is called Ovarian-Adnexal Reporting and Data System (O-RADS)[5].

Despite surgical exploration remaining the gold standard to evaluate disease extension in patients with ovarian cancer, ultrasound demonstrated good sensitivity and specificity in the preoperative assessment of carcinomatosis on the great omentum, parietal peritoneum, diaphragms, and small/large bowel[6].

Figure 1 Ultrasound image of an ovarian lesion with solid morphology, according to IOTA terms. Final histology was positive for benign ovarian lesion (ovarian fibroma).

Figure 2 IOTA ADNEX model applied to the pelvic mass. The risk of malignancy in this case is 2.1% while the chance of benign tumor is 97.9%.

Figure 3 Ultrasound image of a pelvic mass with solid morphology, according to IOTA terms (solid component is more than 80% of whole tumor). Final histology was positive for malignant ovarian tumor (serous ovarian carcinoma).

Figure 4 IOTA ADNEX model applied to the pelvic mass. The risk of malignancy in this case is 93.2% with the highest relative risk corresponding to primary advanced ovarian cancer.

Assessment of gynecologic tumors

The results of this 20-year experience have been recognized by multidisciplinary committee in a consensus statement as ESGO/ISUOG/IOTA/ESGE[7].

Transvaginal ultrasound is considered imaging modality of choice for the assessment of uterine endometrial cancer with high accuracy in the evaluation of myometrial and cervical infiltration[8]. The role of ultrasound in the diagnosis of myometrial malignancies (sarcomas) is still challenging[9] and there is great interest for the upcoming results of enlarged prospective study conducted in our Institution. Ultrasound has gained increased attention also in preoperative staging of more rare tumors like cervical cancer, vaginal cancers or tubal ones. Finally, the ultrasound examination represents the instrument of choice for the surveillance of gynecologic oncology patients, for the detection of pelvic and abdominal recurrences.

For the assessment of primary or recurrences gynecologic tumors, high quality 2D and 3D B-mode are essential to analyze the different anatomical structures. The inclusion of Color Doppler Imaging can reveal important additional information. One of the latest sources available for the examiner is Superb Micro-vascular Imaging (SMI), a new blood flow imaging technique able to minimize motion artifacts by eliminating signals based on analysis of tissue movement. Compared to conventional blood flow imaging such as Color and Power Doppler Imaging, SMI significantly reduces motion artifacts and can visualize low-velocity blood flow in small vessels (Figs. 5 and 6).

Innovative techniques and sophisticated software are opening up new perspectives in the role of the ultrasound examination in gynecologic oncology. For example, fusion technique is an emerging technique that combines real-time ultrasound examination with other imaging modalities, such as Computed Tomography (CT), Magnetic Resonance Imaging (MRI) and Positron Emission Tomography (PET). Application of this imaging modality can enable a more accurate preoperative evaluation of the extension of gynecological tumors without additional cost (Fig. 7)[10].

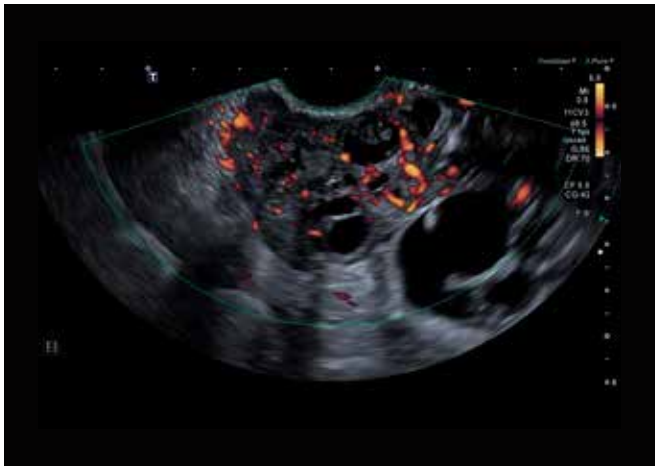

Figure 5 Standard Power Doppler Image of a pelvic mass.

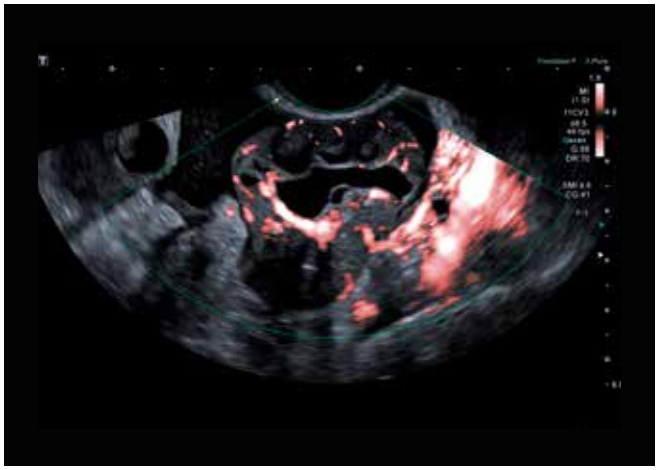

Figure 6 Vascularization of a pelvic mass using SMI.

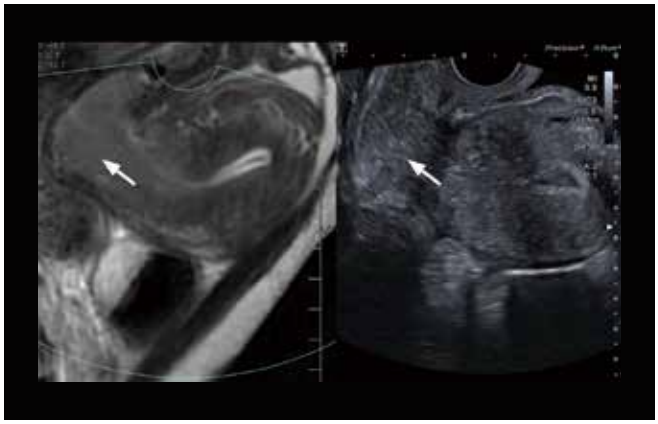

Figure 7 Fusion imaging of magnetic resonance and ultrasound examination of a patient with cervical cancer, indicated in both images with white arrows.

Another innovative tool is the intraoperative ultrasound examination which is able to guide the surgeon in the identification of small lesions not easily visible due to the localization behind intraperitoneal adhesions or in the retroperitoneal areas[11]. This examination can be performed by using small laparotomic probes or laparoscopic ones (Figs. 8 and 9). Finally, transvaginal ultrasound-guided biopsy is a minimally invasive tool that can be used to obtain material for histological diagnosis in patients not eligible for surgery, avoiding unnecessary explorative surgical procedure[12].

A further perspective in gynecology oncology is the radiomics analysis, an emerging and innovative technique of high throughput extraction of a large number of features from medical images. The typical radiomic analysis includes the evaluation of size, shape, and textural features that have useful spatial information on pixel or voxel distribution and patterns. These features are further used in creating statistical models to provide support for individualized diagnosis and management[13].

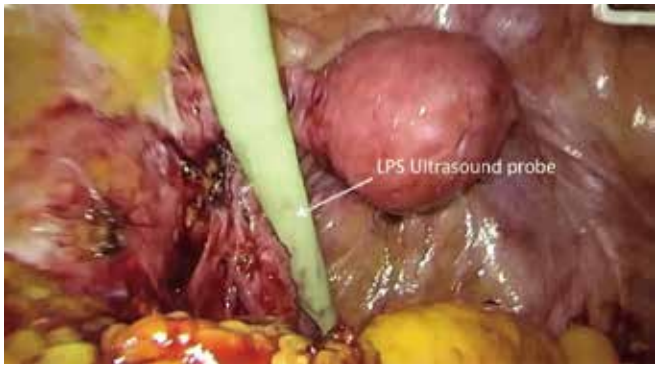

Figure 8 Intraoperative imaging of laparoscopic ultrasound probe.

Figure 9 Different types of probes used during surgery.

Conclusion

In conclusion, in the diagnostic scenario of gynecologic oncology units, ultrasound examination performed with high end technology represents the fundamental imaging method to optimize clinical management. The possibility to include innovative facilities, such as fusion and storage for radiomics analysis in the same equipment could open up new perspectives.

References

1. Timmerman D, Valentin L, Bourne TH, Collins WP, Verrelst H, Vergote I; International Ovarian Tumor Analysis (IOTA) Group. Terms, definitions and measurements to describe the sonographic features of adnexal tumors: a consensus opinion from the International Ovarian Tumor Analysis (IOTA) Group. *Ultrasound Obstet Gynecol.* 2000 Oct;16(5):500-5. doi: 10.1046/j.1469-0705.2000.00287.x. PMID: 11169340.
2. Timmerman D, Ameye L, Fischerova D, Epstein E, Melis GB, Guerriero S, Van Holsbeke C, Savelli L, Fruscio R, Lissoni AA, Testa AC, Veldman J, Vergote I, Van Huffel S, Bourne T, Valentin L. Simple ultrasound rules to distinguish between benign and malignant adnexal masses before surgery: prospective validation by IOTA group. *BMJ.* 2010 Dec 14;341:c6839. doi: 10.1136/bmj.c6839. PMID: 21156740; PMCID: PMC3001703.
3. Wynants L, Timmerman D, Verbakel JY, Testa A, Savelli L, Fischerova D, Franchi D, Van Holsbeke C, Epstein E, Froyman W, Guerriero S, Rossi A, Fruscio R, Leone FP, Bourne T, Valentin L, Van Calster B. Clinical Utility of Risk Models to Refer Patients with Adnexal Masses to Specialized Oncology Care: Multicenter External Validation Using Decision Curve Analysis. *Clin Cancer Res.* 2017 Sep 1;23(17):5082-5090. doi: 10.1158/1078-0432.CCR-16-3248. Epub 2017 May 16. PMID: 28512173.
4. Van Calster B, Van Hoorde K, Valentin L, Testa AC, Fischerova D, Van Holsbeke C, Savelli L, Franchi D, Epstein E, Kaijser J, Van Belle V, Czekierdowski A, Guerriero S, Fruscio R, Lanzani C, Scala F, Bourne T, Timmerman D; International Ovarian Tumour Analysis Group. Evaluating the risk of ovarian cancer before surgery using the ADNEX model to differentiate between benign, borderline, early and advanced stage invasive, and secondary metastatic tumours: prospective multicentre diagnostic study. *BMJ.* 2014 Oct 15;349:g5920. doi: 10.1136/bmj.g5920. PMID: 25320247; PMCID: PMC4198550.
5. Andreotti RF, Timmerman D, Strachowski LM, Froyman W, Benacerraf BR, Bennett GL, Bourne T, Brown DL, Coleman BG, Frates MC, Goldstein SR, Hamper UM, Horrow MM, Hernanz-Schulman M, Reinhold C, Rose SL, Whitcomb BP, Wolfman WL, Glanc P. O-RADS US Risk Stratification and Management System: A Consensus Guideline from the ACR Ovarian-Adnexal Reporting and Data System Cmittee. *Radiology.* 2020 Jan;294(1):168-185. doi: 10.1148/radiol.2019191150. Epub 2019 Nov 5. PMID: 31687921.
6. Moruzzi MC, Bolomini G, Moro F, Mascilini F, Ficarelli S, Beneduce G, Giudice MT, Pasciuto T, Moroni R, Scambia G, Fagotti A, Testa AC. Diagnostic performance of ultrasound in assessing the extension of the disease in patients with suspicion of malignant ovarian tumor: correlation between ultrasound parameters and Fagotti's score. *Int J Gynecol Cancer.* 2021 Feb;31(2):279-285. doi: 10.1136/ijgc-2020-001606. Epub 2020 Sep 7. PMID: 32900793.
7. Timmerman D, Planchamp F, Bourne T, Landolfo C, du Bois A, Chiva L, Cibula D, Concin N, Fischerova D, Froyman W, Gallardo Madueño G, Lemley B, Loft A, Mereu L, Morice P, Querleu D, Testa AC, Vergote I, Vandecaveye V, Scambia G, Fotopoulou C. ESGO/ISUOG/IOTA/ESGE Consensus Statement on pre-operative diagnosis of ovarian tumors. *Int J Gynecol Cancer.* 2021 Jul;31(7):961-982. doi: 10.1136/ijgc-2021-002565. Epub 2021 Jun 10. PMID: 34112736; PMCID: PMC8273689.
8. Epstein E, Fischerova D, Valentin L, Testa AC, Franchi D, Sladkevicius P, Frühauf F, Lindqvist PG, Mascilini F, Fruscio R, Haak LA, Opolskiene G, Pascual MA, Alcazar JL, Chiappa V, Guerriero S, Carlson JW, Van Holsbeke C, Leone FPG, De Moor B, Bourne T, van Calster B, Installe A, Timmerman D, Verbakel JY, Van den Bosch T. Ultrasound characteristics of endometrial cancer as defined by International Endometrial Tumor Analysis (IETA) consensus nomenclature: prospective multicenter study. *Ultrasound Obstet Gynecol.* 2018 Jun;51(6):818-828. doi: 10.1002/uog.18909. Erratum in: Ultrasound Obstet Gynecol. 2018 Nov;52(5):684. PMID: 28944985.
9. Ludovisi M, Moro F, Pasciuto T, Di Noi S, Giunchi S, Savelli L, Pascual MA, Sladkevicius P, Alcazar JL, Franchi D, Mancari R, Moruzzi MC, Jurkovic D, Chiappa V, Guerriero S, Exacoustos C, Epstein E, Frühauf F, Fischerova D, Fruscio R, Ciccarone F, Zannoni GF, Scambia G, Valentin L, Testa AC. Imaging in gynecological disease (15): clinical and ultrasound characteristics of uterine sarcoma. *Ultrasound Obstet Gynecol.* 2019 Nov;54(5):676-687. doi: 10.1002/uog.20270. Epub 2019 Oct 7. PMID: 30908820.
10. Moro F, Gui B, Arciuolo D, Bertoldo V, Borzi R, Romeo P, Petta F, Cambi F, Pasciuto T, Zannoni GF, Valentini V, Manfredi R, Scambia G, Testa AC. Fusion imaging of ultrasound and MRI in the assessment of locally advanced cervical cancer: a prospective study. *Int J Gynecol Cancer.* 2020 Apr;30(4):456-465. doi: 10.1136/ijgc-2019-000902. Epub 2020 Mar 18. PMID: 32193220.
11. Mascilini F, Quagliozzi L, Moro F, Moruzzi MC, Gallotta V, Alletti SG, Scambia G, Testa AC, Fagotti A. Role of Intraoperative Ultrasound to Extend the Application of Minimally Invasive Surgery for Treatment of Recurrent Gynecologic Cancer. *J Minim Invasive Gynecol.* 2018 Jul-Aug;25(5):848-854. doi: 10.1016/j.jmig.2017.12.023. Epub 2018 Jan 8. PMID: 29325966.
12. Mascilini F, Quagliozzi L, Moro F, Moruzzi MC, De Blasis I, Paris V, Scambia G, Fagotti A, Testa AC. Role of transvaginal ultrasound-guided biopsy in gynecology. *Int J Gynecol Cancer.* 2020 Jan;30(1):128-132. doi: 10.1136/ijgc-2019-000734. Epub 2019 Oct 23. PMID: 31645428.
13. Moro F, Albanese M, Boldrini L, Chiappa V, Lenkowicz J, Bertolina F, Mascilini F, Moroni R, Gambacorta MA, Raspagliesi F, Scambia G, Testa AC, Fanfani F. Developing and validating ultrasound-based radiomics models for predicting high-risk endometrial cancer. *Ultrasound Obstet Gynecol.* 2021 Oct 29. doi: 10.1002/uog.24805. Epub ahead of print. PMID: 34714568.

CANON MEDICAL SYSTEMS CORPORATION
https://global.medical.canon

©Canon Medical Systems Corporation 2022. All rights reserved.
Design and specifications are subject to change without notice.
MWPUS0020EA 2022-11 CMSC/Produced in Japan

Canon Medical Systems Corporation meets internationally recognized standards for Quality Management System ISO 9001, ISO 13485. Canon Medical Systems Corporation meets the Environmental Management System standard ISO 14001.

The clinical results described in this paper are the experience of the author.
Results may vary due to clinical setting, patient presentation and other factors.

Some features presented in this document may not be commercially available on all systems shown or may require the purchase of additional options. Please contact your local Canon Medical Systems representative for details.

Made For *life*